are three gizzards, which, like those of *Heliodrilus* and *Hyperiodrilus*, are situated at the junction of the intestine and œsophagus; each gizzard occupies a single segment. These three genera, which belong to Perrier's Intraclitellian group, show that one of the characters made use of to distinguish that group from the Anteclitellians no longer holds. M. Perrier[1] writes:—"Chez les *Lombriciens antéclitelliens* que nous avons étudiés, le gésier s'est toujours trouvé placé *en arrière des organes génitaux* et de leurs organes accessoires, en arrière aussi des anses contractiles ou cœurs latéraux de l'appareil circulatoire. Dans ces Vers, l'œsophage est d'ailleurs très-allongé et la ceinture rejetée relativement très-loin en arrière; quelquefois presque au milieu du corps.

"Au contraire, chez tous les Lombriciens intra- ou postclitelliens, le gésier est placé *en avant des testicules et des ovaires*, c'est-à-dire en avant des *organes essentiels* de la génération. Il est également *en avant des centres d'impulsion du sang*, que ce soient des cœurs dorsaux impairs, comme chez l'*Anteus*, ou des cœurs latéraux, comme chez les autres Lombriciens." Since Dr. Horst has discovered[2] an Intraclitellian earthworm, *Glyphidrilus*, in which the clitellum occupies the "anteclitellian" position, viz. from segment 23–31, it is impossible any longer to retain the group "Anteclitelliens."

It is clear, from this brief account of the salient features in the structure of *Libyodrilus*, that it forms a quite new generic type, concerning the particular affinities of which I do not for the present offer any suggestion.

## 7. On a Functional Ductus Botalli in *Nycticorax violaceus* and *Dafila spinicauda*. By Frank Finn, B.A., late Scholar of Brasenose College, Oxford. (Communicated by F. E. Beddard, F.Z.S., Prosector to the Society.)

[Received February 17, 1891.]

In his memoir on the "Development of the Branchial Arches in Birds," published in the Transactions of the Royal Society of London for 1888, Dr. J. Mackay has described and figured an abnormality which he met with in the dissection of a Guillemot (*Lomvia troile*). This consisted in the existence of "the remains of the dorsal connection between the third and fourth arches upon the right side," "as a distinct cord passing between the common carotid artery and the descending portion of the aortic arch." Dr. Ferdinand Hochstetter also records two obliterated ductus botalli in *Aquila nævia* and *Circus cineraceus* ("Ueber den Ursprung der Arteria subclavia der Vögel," Morph. Jahrb. xvi. p. 484, 1890).

[1] "Mémoires pour servir etc.," Nouv. Arch. Mus. t. viii. p. 156.
[2] Nederl. Dierk. Vereen. Verslag. op. d. Vergad. v., 26 Oct. 1889.

Within the last few months I have come upon two cases of an abnormality similar to the above, but still more marked, inasmuch as instead of a cord a functional vessel was present. In the first instance, which occurred in a Violaceous Night-Heron (*Nycticorax violaceus*), the deviation from the ordinary arrangement was very marked, as is well shown in the figure, which was drawn from the injected specimen by Mr. Harrison, under my supervision. The right carotid was very large at its origin, and ran for about an inch towards the left (this portion of the vessel being marked in the figure by an asterisk), when it turned almost at right angles and ran forward in the usual manner, giving off at the turning point the right vertebral, and a rather larger vessel which ran back to join the dorsal aorta at the base of the heart. In the figure the heart is removed, and the aorta pulled forward to show this junction. Injection proved that this connecting duct had a lumen and was thus quite functional, though apparently not of equal

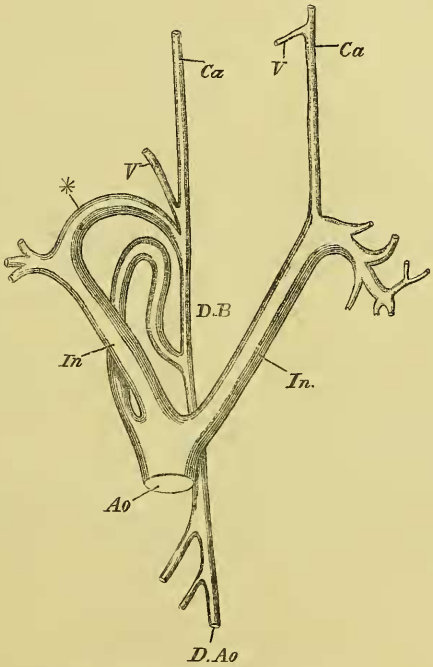


Carotids of *Nycticorax violaceus.*

*Ca*, carotids; *V*, vertebrals; *D.B*, ductus botalli; *In*, innominates; *D.Ao*, dorsal aorta. The * marks the enlarged part of the right carotid.

calibre throughout. The vertebrals (*V*, *V*), though given off so far apart, reached the spinal column at about the same point; nor did I observe any abnormality in the vessels of the left side.

The appearance of the abnormal vessels in the other specimen, a Chilian Pintail (*Dafila spinicauda*), though the abnormality was essentially the same, was less striking; the right carotid ran towards the left as in the Heron, for a short distance, but seemed relatively smaller and straighter; but it similarly turned suddenly forwards, at the point of giving off the vertebral, and sent a vessel backwards to the dorsal aorta, which it joined, at the left side of it opposite the base of the heart. This specimen was not injected, but I was able, by passing a bristle down the tube, to satisfy myself that the connection between the carotid and the aorta was a functional one. I also noted that in this specimen the artery supplying the skin of the neck sprang, on the right side, from the same point as the vertebral, while on the left it was smaller and given off a little posteriorly to the vertebral. A ductus arteriosus stretched from the left side of the dorsal aorta to the left pulmonary artery. Professor G. B. Howes has kindly drawn my attention to Professor Turner's paper on *Globiocephalus svineval* (Journ. Anat. & Phys. ii. p. 66, 1868), in which the existence of a closed *ductus arteriosus* between the aorta and pulmonary artery is recorded as occurring in that Cetacean. Messrs. Marshall and Hurst also mention it in the Rabbit.

Although I have dissected examples of upwards of 90 species, the above is the only abnormal variation in the carotids which I have observed; and that in the two specimens in which it occurred it can only be regarded as an individual peculiarity I have had ample opportunities of proving, having dissected three other specimens of *Nycticorax violaceus* and one other of *Dafila spinicauda*, besides two specimens of *Nycticorax griseus* and one of *Dafila bahamensis*, none of which exhibited this abnormality. I find, too, that the late Prof. Garrod has examined the three first-named species, besides *Nycticorax caledonicus*, and has not recorded any abnormality in their carotids.

It would seem therefore that this approach to the reptilian structure does not characterize any particular species or genus, but is liable to appear sporadically in individual specimens of species belonging to widely separated groups.

In conclusion, I have to express my thanks to the Society for the facilities for study which they have afforded me, and in particular to their Prosector, without whose kind tuition and assistance this communication would have been impossible.

---